Prolonged Neonatal Jaundice

Ahmed Laving

Prolonged Jaundice?

- >6 months
- >3 months
- >2 weeks
- >4 weeks

Prolonged Jaundice?

- >6 months
- >3 months
- >2 weeks
- >4 weeks

Case Presentation

- 6 week old born in UK via c/section to a primi-gravida
- Jaundice from week 2 of life; reassured by midwife visits at home
- Returned to Kenya and brought for well baby visit/vaccination at 6 weeks
- Noted to have jaundice; otherwise well
- Stool colour reported as normal by mother
- What’s your next step?

Case Presentation (2)

- Stool colour: pale
- Differential diagnosis?
- Investigations?
- Treatment: ?expose to sunlight

Prolonged Neonatal Jaundice

- Jaundice persisting for >2 weeks in a term infant, and >3 weeks in a preterm infant
- Needs urgent evaluation
- About 2.4-9% of exclusively breast-fed babies may have jaundice beyond 2 weeks of age (unconjugated)

Winfield CR. Clinical study of jaundice in breast and bottle fed babies. *Arch Dis Child 1978*

Neonatal Cholestasis

- Defined as conjugated hyperbilirubinaemia developing within 60 days of birth
- Conjugated bilirubin >20% of total bilirubin
- Cholestatic jaundice affects 1 in 2500 infants
- Guidelines recommend evaluation of every neonate with jaundice > 2 weeks of age

Naspghan Guidelines JPGHN 2004

Aetiology

- Basic distinction is between:
  - Extra-hepatic aetiologies
  - Intra-hepatic aetiologies

Extra-hepatic Causes

- *Extra-hepatic biliary atresia*
- *Choledochal cyst*
- Inspissated bile/mucus plug
- Cholelithiasis
- Cystic fibrosis
- Congenital hepatic fibrosis

Intra-hepatic Causes

- Infectious
  - *Idiopathic neonatal hepatitis syndrome*
  - TORCHES
  - Hepatitis B,C
  - Sepsis
  - *E.coli UTI*
- Endocrine
  - *hypothyroidism*
- Metabolic
  - *Galactosaemia*
  - Tyrosinaemia
  - Alpha1antitrypsin def.
  - Haemachromatosis
- Congenital
  - Alagille's syndrome
- Toxic
  - TPN associated
- Idiopathic

Clinical Presentation

- Jaundice >2 weeks
- ***Acholic stools***
- ***Dark urine***
- +/- Lethargy, irritability
- Bleeding tendency
- Scleral icterus
- +/- Pallor
- Hepatomegaly
- ?dysmorphic features
- +/- failure to thrive

Stool colour

- Parents not reliable observers of stool colour
- Clinicians better at detecting acholic stool
- Stool colour card improves early case finding

Crofts DJ. Assessment of stool colour in community management of prolonged jaundice in infancy. *Acta Paediatr 1999;88*

Infant Stool Color Card

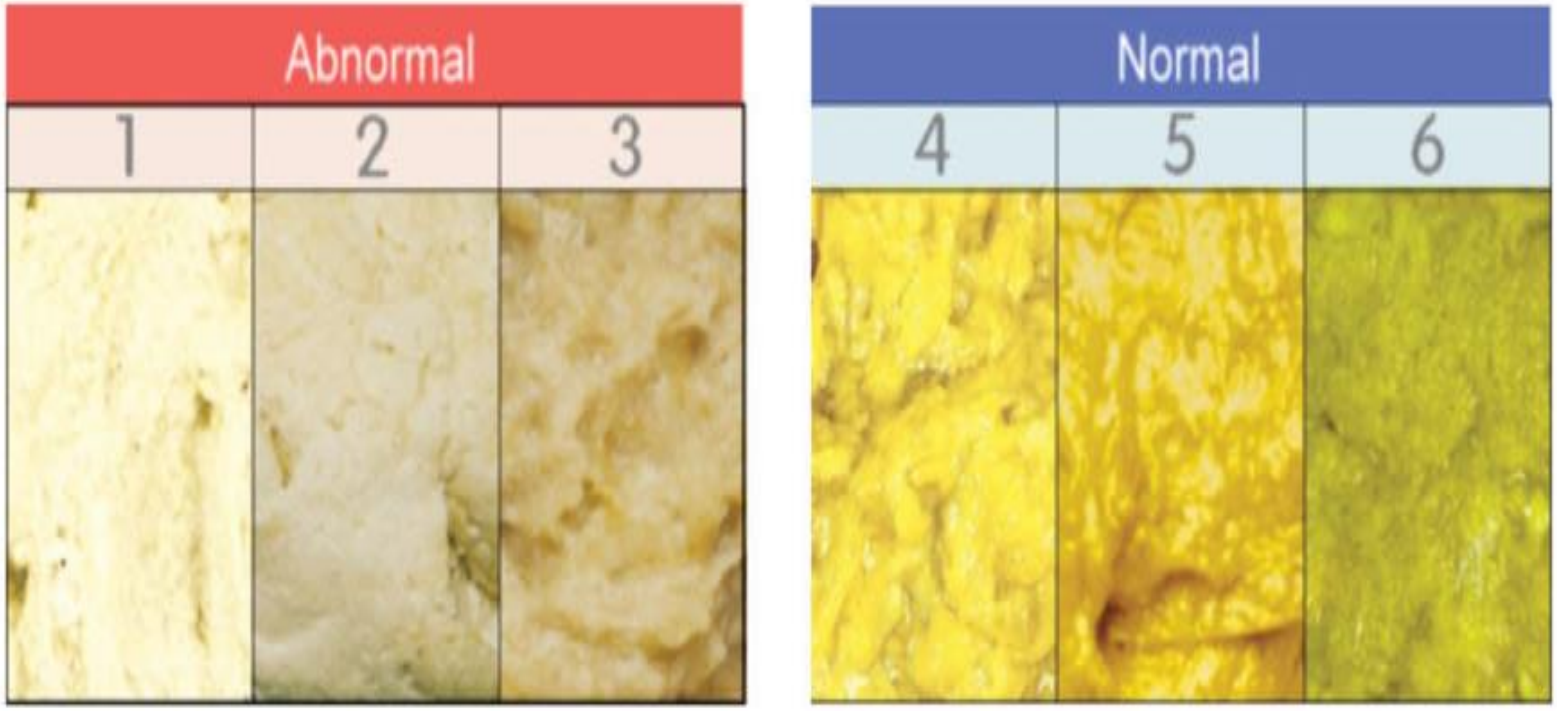

Goals of Timely Evaluation

- Diagnose and treat known medical and/or life-threatening conditions
  - *Hypothyroidism*
  - Galactosaemia
  - *UTI*
  - Sepsis
- Identify disorders amenable to surgical therapy within an appropriate time-frame
  - Choledochal cyst
  - *Biliary atresia*

Initial Evaluation of Jaundiced Infant

Initial Evaluation of Jaundiced Infant

Is the infant ill looking?

- Sepsis
- Galactosaemia
- Haemolysis

ADMIT

If infant stable:

- Bilirubin: total/direct
  - If cholestatic, urgent!
- LFT's, PTI, Albumin, RBS
- FBC, Urine mcs, TSH
- Abdominal US
- Liver biopsy
- Others

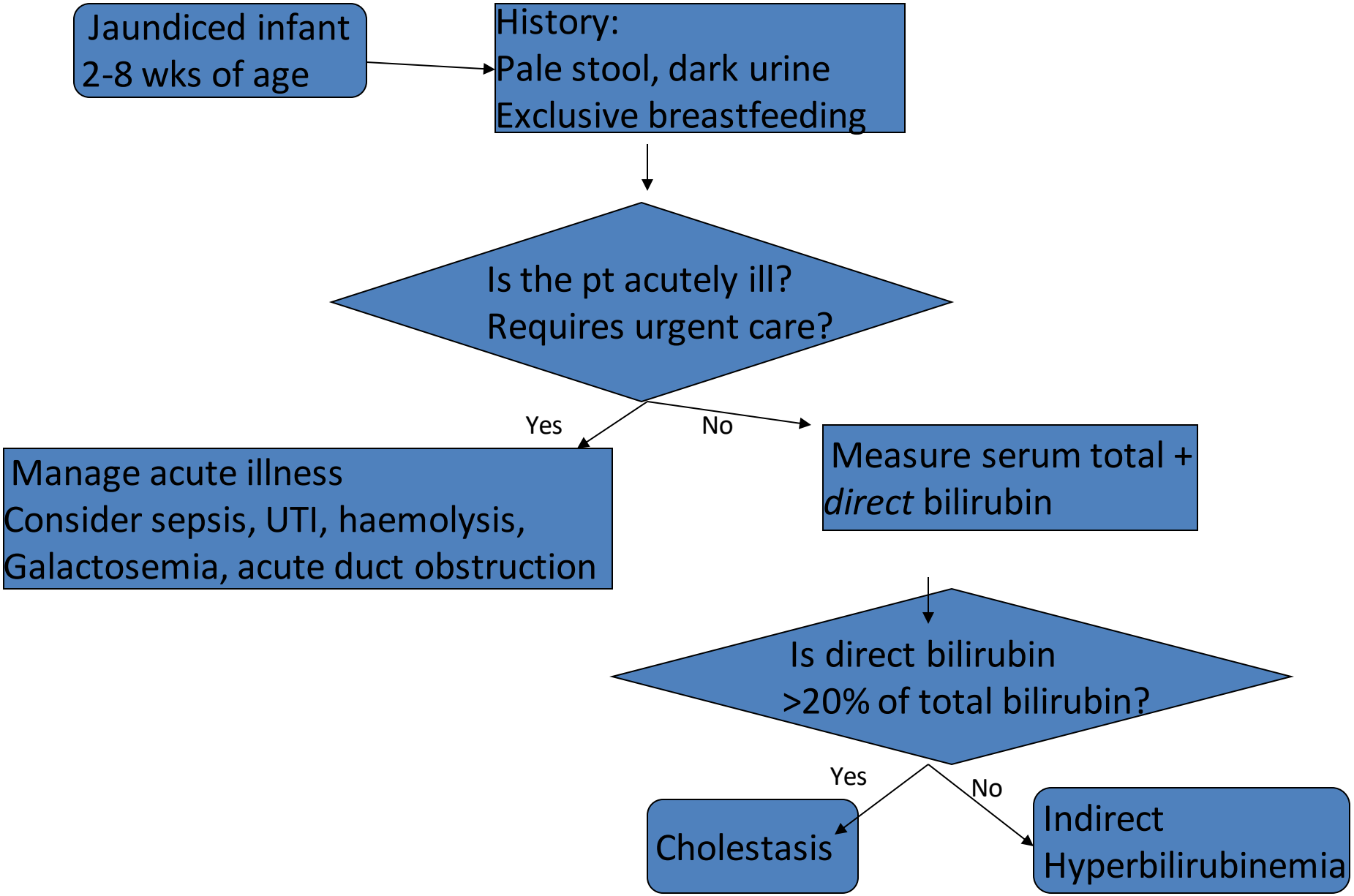
Jaundiced infant
2-8 wks of age
History:
Pale stool, dark urine
Exclusive breastfeeding
Is the pt acutely ill?
Requires urgent care?
Yes
No
Manage acute illness
Consider sepsis, UTI, haemolysis,
Galactosemia, acute duct obstruction
Measure serum total +
direct bilirubin
Is direct bilirubin
>20% of total bilirubin?
Yes
No
Cholestasis
Indirect
Hyperbilirubinemia

CHOLESTASIS

Consider biliary atresia, choledochal cyst, galactosaemia, hypothyroidism, UTI

Investigations:
FBC, LFT, PTI, Albumin, Glucose
Urine reducing substances + m/c/s
Thyroid profile, ferritin levels
Abdominal Ultrasound, TORCH
Liver biopsy, Others

Consult appropriately:
Paediatric GI
Paediatric Surgeon
Paediatric Metabolic Expert

INDIRECT HYPERBILIRUBIN

Consider breast milk jaundice, UTI, ABO incompatibility, hypothyroidism

Investigations:
FBC, LFT, PTI, Albumin, Glucose
PBF + Blood Group + Coomb's test
Septic screen, Urine m/c/s
Thyroid profile, Others

Consult appropriately

Abdominal Ultrasound

- Fasting (3-4 hours)
- If gall bladder contracted/not visualized, suggestive of Biliary Atresia (73-100% sensitivity, 67-100% specificity)
- “Triangular cord” sign: fibrous cone of tissue at bifurcation of portal vein (83-100% sensitivity, 98-100% specificity to detect biliary atresia)
- Detects choledochal cysts

Naspghan Guidelines JPGHN 2004

Radionucleide scan

- Hepatobiliary scintigraphy
  - Premedicate with phenobarbital 5mg/kg/d
  - Demonstrate uptake into and excretion from the liver
  - Costly

- MRCP

Liver biopsy

- High sensitivity (96%) and sensitivity (92%) for Biliary Atresia
- Also helpful in diagnosing neonatal hepatitis syndrome, and other metabolic conditions

Dehgani SM. Comparison of different diagnostic methods in infants with cholestasis. World J Gastroenterol 2006

Treatment

- Medical management
  - Nutritional support
  - Treatment of pruritus
  - Choleretics and bile acid-binders
  - Management of portal hypertension and its consequences
- Specific treatment depends on aetiology

Nutritional Treatment

- Adequate calories and protein
- Supplement calories with medium chain triglycerides
- Maintain levels of essential long-chain fatty acids
- Treatment and/or prophylaxis for fat-soluble vitamin deficiencies

Summary

- Cholestatic jaundice should be excluded in all infants with prolonged jaundice >14 days
- Infantile cholestasis needs early recognition and diagnostic evaluation:
  - Early treatment of medical conditions
  - short window period for surgical treatment
- No role of “sunlight phototherapy” beyond 2 weeks of age

Thank You!

Homework

- Biliary atresia
- Hypothyroidism
- Galactosemia

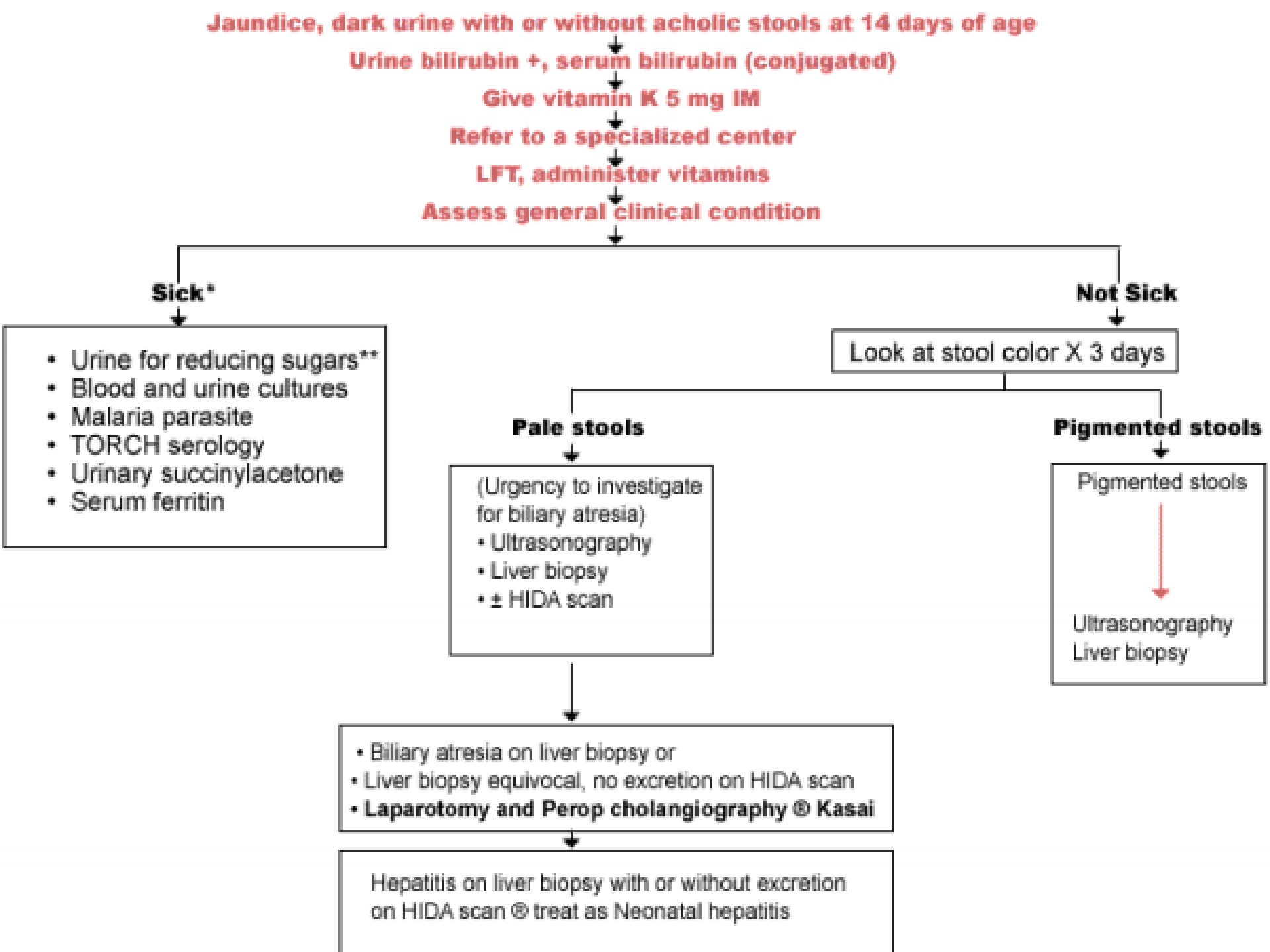
Jaundice, dark urine with or without acholic stools at 14 days of age
Urine bilirubin +, serum bilirubin (conjugated)
Give vitamin K 5 mg IM
Refer to a specialized center
LFT, administer vitamins
Assess general clinical condition
Sick*
Not Sick
• Urine for reducing sugars**
• Blood and urine cultures
• Malaria parasite
• TORCH serology
• Urinary succinylacetone
• Serum ferritin
Look at stool color X 3 days
Pale stools
Pigmented stools
(Urgency to investigate for biliary atresia)
• Ultrasonography
• Liver biopsy
• ± HIDA scan
Pigmented stools
Ultrasonography
Liver biopsy
• Biliary atresia on liver biopsy or
• Liver biopsy equivocal, no excretion on HIDA scan
• Laparotomy and Perop cholangiography ® Kasai
Hepatitis on liver biopsy with or without excretion on HIDA scan ® treat as Neonatal hepatitis